

# Multiple Injections of Leukoreduced Platelet Rich Plasma Reduce Pain and Functional Impairment in a Canine Model of ACL and Meniscal Deficiency

James L. Cook,<sup>1</sup> Patrick A. Smith,<sup>2</sup> Chantelle C. Bozynski,<sup>1</sup> Keiichi Kuroki,<sup>1</sup> Cristi R. Cook,<sup>1</sup> Aaron M. Stoker,<sup>1</sup> Ferris M. Pfeiffer<sup>1</sup>

<sup>1</sup>Comparative Orthopaedic Laboratory, University of Missouri, Columbia, Missouri, <sup>2</sup>Columbia Orthopaedic Group, Columbia, Missouri

Received 8 July 2015; accepted 21 September 2015

Published online 2 October 2015 in Wiley Online Library (wileyonlinelibrary.com). DOI 10.1002/jor.23054

**ABSTRACT:** Platelet rich plasma (PRP) is used to treat many musculoskeletal disorders. We used a canine model to determine the effects of multiple intra-articular injections of leukoreduced PRP (ACP) on anterior cruciate ligament healing, meniscal healing, and progression of osteoarthritis (OA). With Animal Care and Use Committee (ACUC) approval, 12 dogs underwent partial ACL transection and meniscal release in one knee. At weeks 1, 2, 3, 6, and 8 after insult, dogs were treated with intra-articular injections (2 ml) of either ACP ( $n = 6$ ) or saline ( $n = 6$ ). Dogs were assessed over 6 months to determine comfortable range of motion (CROM), lameness, pain, effusion, kinetics, and radiographic and arthroscopic assessments. At 6-month endpoint, dogs were assessed for ACL material properties and histopathology. Saline-treated dogs had significantly ( $p < 0.04$ ) more CROM loss, significantly ( $p < 0.01$ ) more pain, significantly ( $p < 0.05$ ) more severe lameness, significantly ( $p < 0.05$ ) lower function, and significantly ( $p < 0.05$ ) lower %Total Pressure Index in affected hindlimbs compared to ACP-treated dogs. Radiographic OA increased significantly ( $p < 0.01$ ) over time within each group. Arthroscopically, saline-treated knees showed moderate to severe synovitis, further ACL disruption, and medial compartment cartilage loss, and ACP-treated knees showed evidence of ACL repair and less severe synovitis. ACL material properties in ACP-treated knees were closer to normal than in saline-treated knees, however, the differences were not statistically significant. ACL histopathology was significantly ( $p < 0.05$ ) less severe in ACP-treated knees compared to saline-treated knees. Five intra-articular injections of leukoreduced PRP had beneficial effects for ACL healing, improved range of motion, decreased pain, and improved limb function for up to 6 months in this model. © 2015 Orthopaedic Research Society. Published by Wiley Periodicals, Inc. *J Orthop Res* 34:607–615, 2016.

**Keywords:** platelet rich plasma; intra-articular injection; knee; anterior cruciate ligament; osteoarthritis

Platelet rich plasma (PRP) is receiving tremendous attention along with increasing use for treatment of many different musculoskeletal disorders.<sup>1–11</sup> There is now convincing evidence for the safety and efficacy of PRP as an intra-articular injection for the treatment of osteoarthritis.<sup>1–9</sup> PRP—alone or with a scaffold—has also been used intra-articularly in an attempt to augment ACL healing after primary repair or reconstruction.<sup>6–10,12</sup> Results of these studies have shown lack of efficacy for use of PRP alone after suture repair of surgically created ACL tears in animal models.<sup>10,12</sup> However, encouraging results have been reported for PRP with a scaffold for enhancing ACL repair in similar models.<sup>10,13–15</sup> Further, PRP alone or with a scaffold was reported to be effective for enhancing ACL graft healing in some animal models of complete ACL reconstructions using autografts,<sup>15–21</sup> while it was not beneficial in other models.<sup>22</sup> In studies evaluating clinical patients undergoing ACL reconstruction, PRP treatment has been reported to be associated with improved graft maturation, better synovial coverage, greater graft width and higher graft tension, however, no improvements in clinical outcomes or bone-tendon healing were noted.<sup>23–32</sup>

With respect to the meniscus, PRP incorporated in a hydrogel showed positive effects on meniscal defect healing in a rabbit model.<sup>33</sup> In addition, PRP has chemotactic, anabolic, anti-inflammatory, and anti-

degradative effects, which also may be beneficial for meniscal healing and/or preservation of its integrity and function.<sup>2,34–38</sup> Similar to the ACL, direct effects of PRP on meniscal healing are likely dependent upon sustained local delivery of bioactive factors to the repair site.<sup>2,33–38</sup> As such, a scaffold for PRP delivery and residence at the meniscal defect is thought to be advantageous for promoting tissue repair, whereas intra-articular injection of PRP alone may be sufficient for producing menisco-protective effects.

Encompassed within the goals for treatment of ACL and meniscal pathology is the overriding objective for preservation of whole-joint health and prevention or retardation of the development and progression of OA. In leukoreduced forms, PRP has consistently been reported to have beneficial effects when used for treatment of knee OA.<sup>1–9,34–39</sup> These beneficial effects occur via direct and indirect mechanisms, including stimulation of tissue anabolism, amelioration of tissue catabolism, anti-inflammatory effects, analgesia, and enhancement of viscoelastic properties.<sup>1–9,34–39</sup> Therefore, pre-emptive intra-articular injection of PRP may have significant benefits for patients with ACL and/or meniscal injuries in terms of tissue healing and prevention of post-injury OA. To the authors' knowledge, intra-articular injection of leukoreduced PRP to treat ACL and meniscal tears without repair or reconstruction—and ameliorate the development and progression of osteoarthritis—has not been reported in the peer-reviewed literature. The objective of this study was to determine the effects of multiple intra-articular injections of a leukoreduced PRP on ACL healing, meniscal healing, and amelioration of OA in a

Correspondence to: James L. Cook (T: +573-884-4689; F: +573-882-1760; E-mail: cookjl@missouri.edu)

© 2015 Orthopaedic Research Society. Published by Wiley Periodicals, Inc.

canine model. We hypothesized that multiple intra-articular injections of a leukoreduced PRP significantly reduce pain, improve functional limb use, promote ACL, and meniscal repair, and ameliorate progression of OA compared to saline injections.

## MATERIALS AND METHODS

With our institution's Animal Care and Use Committee approval, adult purpose-bred research hounds (2–5 years of age, 20–27 kg; Marshall Farms BioResources, North Rose, NY, 145 USDA #21-A-008) ( $n=12$ ) were premedicated, anesthetized, and prepared for aseptic arthroscopic knee surgery. Standard cranio (antero) lateral and anteromedial portals were established in the right knee to perform partial transection of the ACL and meniscal release. For partial ACL transection, an arthroscopic scissors was inserted through the anteromedial instrument portal and used to transect the anteromedial bundle of the ACL at its approximate mid-point (Fig. 1A). For meniscal release, an arthroscopic meniscal knife was used to create a complete radial transection of the caudal (posterior) horn of the medial meniscus at its junction with the posterior meniscotibial ligament (Fig. 1B). The left knee served as an unoperated control. Analgesics—morphine (0.5 mg/kg IM) at the time of recovery from anesthesia and within 6 h of the first dose, and tramadol (2–4 mg/kg PO) 6 h following the last morphine dose and then repeated every 12 h—were administered to the dogs for 3 days after surgery. The dogs were returned to their individual kennels and allowed unrestricted activity in the approximately 18–25 square foot runs. Dogs were also individually hand-walked for 15 min in an indoor facility each weekday for the duration of the study.

### Treatment

At weeks 1, 2, 3, 6, and 8 after surgery, dogs were sedated for aseptic intra-articular injection of the right knee in an effort to investigate a maximal number of clinically feasible injections. Dogs were randomly assigned to one of two treatment groups:

- Platelet rich plasma (autogenous conditioned plasma (ACP), Arthrex, Naples, FL) ( $n=6$ ): 2 ml of leukoreduced PRP prepared using ACP syringes and centrifuge (15 ml of whole blood from jugular venipuncture using a 19g butterfly catheter without ACDA spun at 1500 × 5 min) was injected into the right knee after synovial fluid was aspirated to ensure intra-articular placement. Complete blood count performed on ACP samples from each dog revealed mean ACP platelet: whole blood platelet of 2.5

(range, 1.9–2.8) and mean ACP platelet: white blood cell of 296 (range, 180–400) verifying the injectates to be leukoreduced PRP.

- Saline ( $n=6$ ): 2 ml of sterile 0.9% saline was injected into the right knee after synovial fluid was aspirated to ensure intra-articular placement.

### Outcome Measures

Orthopedic examination by a board-certified veterinary orthopaedic surgeon who was blinded to treatment was performed on each dog prior to inclusion in the study. All limbs and joints were assessed clinically and radiographically to ensure that no pre-existing orthopaedic disorders were evident. The following outcome measures were performed pre-operatively, prior to first treatment, and at 1, 2, 6, 12, 18, and 24 weeks after first treatment:

- **Stifle (Knee) Comfortable Range of Motion (CROM)** was measured using a goniometer. With the dog standing, one limb of the goniometer was placed along the lateral axis of the tibia and the other arm placed along the lateral axis of the femur with the hinge-point centered over the joint line. The knee was then manually extended to the highest angle the dog tolerated without showing resistance or pain. The extension angle (degrees) noted on the goniometer at this point was recorded. The knee was then manually flexed to the most acute angle the dog tolerated without showing resistance or pain. The flexion angle (degrees) noted on the goniometer at this point was recorded. The flexion angle was subtracted from the extension angle to determine CROM for each knee.
- **Clinical Lameness Scores** were determined for each dog based on visual examination of gait by the same board-certified veterinary orthopaedic surgeon using a 10 cm visual analogue scale (VAS) for function<sup>40,41</sup> and a validated grading system:

0—no observable lameness

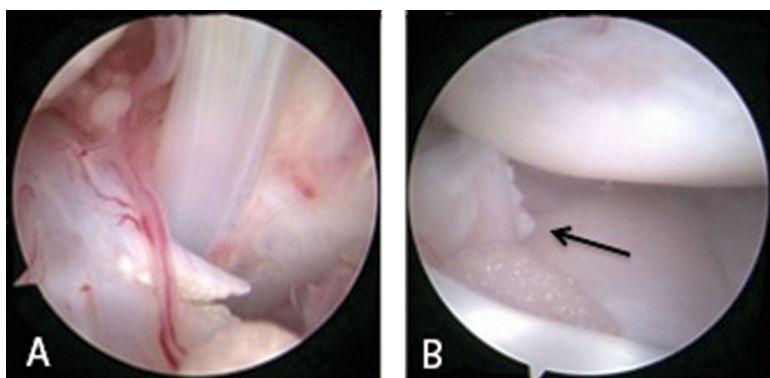
1—intermittent, mild weightbearing lameness with little, if any, change in gait

2—moderate weightbearing lameness—obvious lameness with noticeable gait change

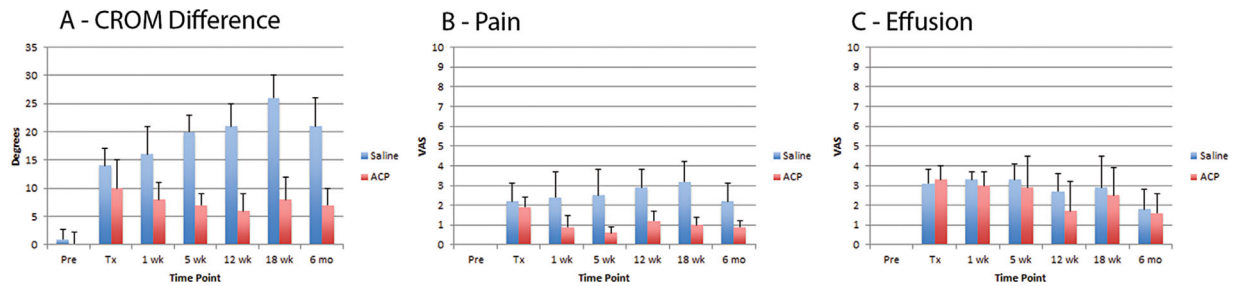
3—severe weightbearing lameness—“toe-touching” only

4—non-weightbearing.

- **Knee Pain and Effusion** were assessed subjectively based on a VAS scale and recorded for each hindlimb of each dog. To assess level of knee pain, the blinded



**Figure 1.** For partial ACL transection (A), an arthroscopic scissors was inserted through the anteromedial instrument portal and used to transect the anteromedial band of the ACL at its approximate mid-point. For meniscal release (B), an arthroscopic meniscal knife was used to create a complete radial transection of the posterior horn of the medial meniscus at its junction with the posterior meniscotibial ligament (arrow).



**Figure 2.** Mean ± SD values for comfortable range of motion differences (A), pain (B), and effusion in the knees of dogs in the Saline and ACP treatment groups over the 6-month study period. Dogs in the Saline group had significantly ( $p < 0.04$ ) greater loss (1.4–3.7×) in CROM compared to ACP dogs beginning 1 week after treatment and at each assessment time point throughout the study period. Dogs in the Saline group had significantly ( $p < 0.01$ ) more pain (2.4–4.2×) in the affected knees compared to ACP dogs beginning 1 week after treatment and at each assessment time point throughout the period. There were no statistically significant differences in degree of effusion. (\* indicates significant differences between groups).

observer palpated and performed CROM on each knee of each dog while assessing responses associated with pain in dogs (i.e., tensing muscles, resisting, flinching, yelping, turning to look, turning to bite) and then observer records perceived level of pain on a VAS scale.<sup>40</sup> To assess degree of knee effusion, the blinded observer palpated the knee of each dog for intra-articular swelling based on standard anatomical landmarks and then recorded the perceived level of effusion on a VAS scale.<sup>41</sup>

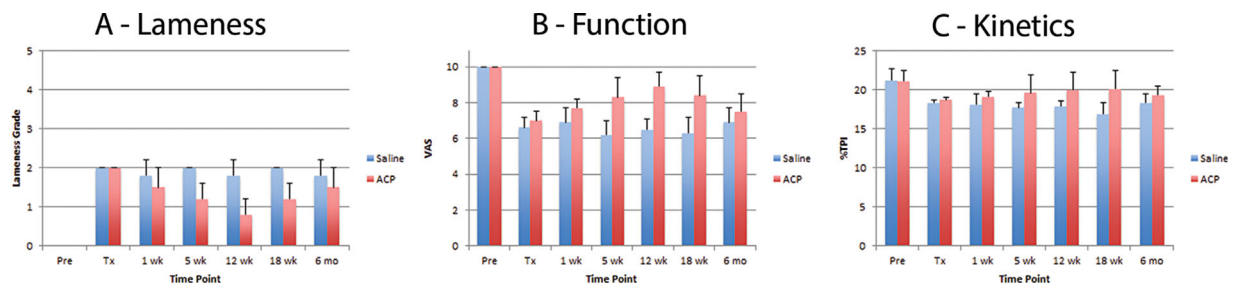
- **Gait Analysis Kinetics** were analyzed by trotting dogs on a pressure-sensing walkway (GAITFour, Haverton, PA) until three complete data sets were obtained and the mean determined. Mean percent body weight distribution was determined for each limb using the three complete data sets based on total pressure index (TPI), and %TPI for the operated limb was chosen a priori as the variable for reporting.

Pre-operatively, prior to first treatment, and at 12 and 24 weeks post-treatment, anteroposterior, and mediolateral radiographic views of the operated knee of each dog were obtained and assessed by one board-certified veterinary radiologist, blinded to the experimental design, using a modified subjective scoring system. Nine regions within both stifles were examined: Femoral trochlea, medial femoral condyle, lateral femoral condyle, medial femoral epicondyle, lateral femoral epicondyle, proximal patella, distal patella, lateral tibial condyle, and medial tibial condyle. Each region was given a score of 0 (normal) to 3 (severe) for each stifle joint. In addition, joint effusion was scored using the same 0–3 categorical range. Scores for each stifle were added to

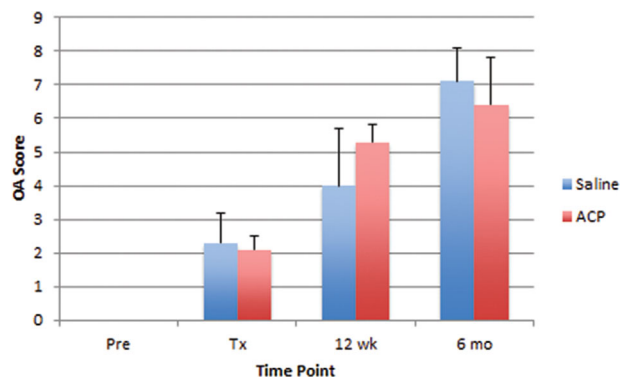
determine the total radiographic OA score for the joint. A total score of 9–10 indicates “Mild OA,” a score of 11–20 indicates “Moderate OA,” and a score of 21–30 indicates “Severe OA.”

Prior to treatment and at 12 and 24 weeks after first treatment, arthroscopic assessment of the right knee of each dog was performed using a standard anterolateral camera portal. All articular surfaces of the patella, femur, and tibia were examined and assessed with respect to degree of articular cartilage damage using the International Cartilage Repair Society (ICRS) cartilage injury classification system.<sup>42</sup> Meniscal and synovial pathology were also arthroscopically assessed and described in terms of nature, extent, and location based on the Osteoarthritis Research Society International (OARSI) system.<sup>43</sup>

At 24 weeks after first treatment, dogs were humanely euthanized by intravenous injection of a sodium pentobarbital-based euthanasia solution. The hindlimbs were then disarticulated at the hip and carefully dissected to remove all soft tissues from around the knee other than the ACL. The ACL was left intact for subsequent biomechanical testing. For each knee (operated and non-operated) of each dog, the femur was held rigid to the materials testing machine (Instron, Norwood, MA) and oriented at a physiologic stance angle (140° relative to the tibia) using custom fixtures. The tibia was attached to the machine’s ram. Quasi-static anterior tension was applied to the tibia along the axis of the ACL at a rate of 0.1 mm/s until 10N pre-load was obtained. Subsequently, quasi-static axial tension was applied to the tibia at a rate of 0.1 mm/s until 4mm relative anterior displacement (between femur and tibia) was measured using



**Figure 3.** Mean ± SD values for lameness (A), function (B), and %Total Pressure Index for dogs in the Saline and ACP treatment groups over the 6-month study period. Dogs in the Saline group had significantly ( $p < 0.05$ ) more severe lameness in the affected hindlimbs compared to ACP dogs at 5, 12, and 18 weeks after treatment. Dogs in the ACP group had significantly ( $p < 0.05$ ) higher function (10 cm VAS scale<sup>40,41</sup>) in the affected hindlimbs compared to Saline dogs at 5, 12, and 18 weeks after treatment. Dogs in the ACP group had significantly ( $p < 0.05$ ) higher %TPI in the affected hindlimbs compared to Saline dogs at 5, 12, and 18 weeks after treatment. (\* indicates significant differences between groups).



**Figure 4.** Mean  $\pm$  SD values for radiographic OA severity scores in the knees of dogs in the Saline and ACP treatment groups over the 6-month study period. Severity of radiographic OA increased significantly ( $p < 0.01$ ) over time within each group, however, no statistically significant differences were noted between groups.

optical tracking (OptoTrak; NDI International, Waterloo, Ontario, Canada). Load at 1 mm, 2 mm, 3 mm, and 4 mm of displacement and stiffness calculations were obtained for each knee tested. Four mm maximal displacement was based on previously published data suggesting that anterior displacements greater than 4 mm in large breed dogs are associated with clinical failure.<sup>44–46</sup> Importantly, this sub-failure, clinically relevant method of testing also allowed for matched histologic assessments on all samples.

ACL, synovia, menisci and bone samples were allowed to fix for at least 3 days in 10% neutral buffered formalin fixative. Medial and lateral menisci, the medial and lateral femoral condyles, and medial and lateral tibial condyles were each divided into 3 sections approximately 2–3 mm thick, and then placed in 10% ethylenediaminetetraacetic acid (EDTA) decalcifying agent until softened (approximately 10 days for menisci and 4 weeks for bones). After decalcification was complete, menisci and bone sections were processed, embedded in paraffin, microtome sectioned (4–6  $\mu$ m) and stained (hematoxylin and eosin [H&E] and Toluidine Blue). Synovial tissue was routinely processed, sectioned (4  $\mu$ m) and stained (H&E), while ACL tissue was routinely processed, sectioned (4  $\mu$ m) and stained (H&E and Toluidine Blue). Histologic scoring of all joint tissues was performed by two board-certified veterinary pathologists, blinded to treatments, using the OARSI histologic scoring system for canine OA for synovia, menisci, femoral condyles, and tibial plateaus.<sup>43</sup> A total score for each joint was derived by adding

all category scores, while the histologic scoring system for cruciate ligaments was used for ACL tissue.<sup>47</sup> The mean scores from the two pathologists were used for statistical analyses.

#### Statistical Analyses

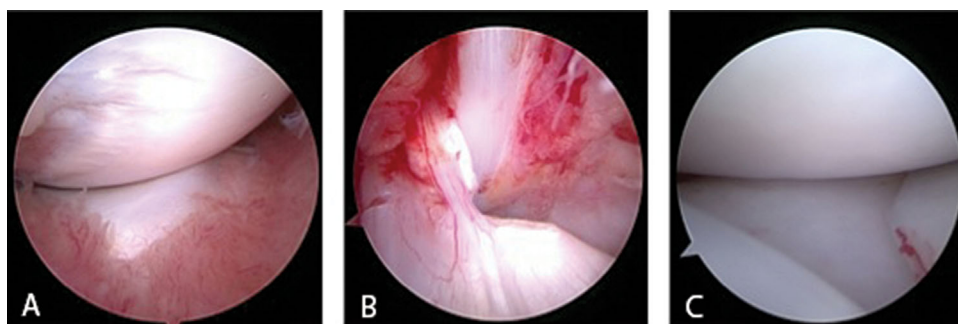
The investigators remained blinded to treatment until all assessments were completed and data were collected and compiled. They were then unblinded to perform statistical analyses, comparing treatment groups. Mean  $\pm$  standard deviation (SD) was determined for each outcome measure, time point, and group. Within group comparisons over time were done using repeated measures ANOVA for continuous data or repeated measures ANOVA on ranks for categorical data. Between group comparisons were done using *t*-Test or one-way ANOVA for continuous data and ANOVA on ranks or rank sum for categorical data. Tukey's post hoc tests were used. Differences with  $p < 0.05$  were considered statistically significant.

#### RESULTS

All dogs underwent surgery, all treatments, and survived for the intended duration of the study. One dog in the saline group developed a markedly swollen knee with severe lameness after the second injection. Synovial fluid was obtained for microbial culture, which produced no growth. The dog was treated with joint lavage (1L sterile saline) and oral antibiotics (Clavamox 22 mg/kg po BID 14 days). The swelling and lameness improved within 3 days and the dog completed the remainder of the study as intended.

#### CROM, Pain, and Effusion

The difference in CROM between hindlimbs for each dog was used for comparison between groups. Dogs in the Saline group had significantly ( $p < 0.04$ ) greater loss (1.4 $\times$ –3.7 $\times$ ) in CROM compared to ACP dogs beginning 1 week after treatment and at each assessment time point throughout the 6-month post-treatment study period (Fig. 2A). Dogs in the Saline group had significantly ( $p < 0.01$ ) more pain (2.4 $\times$ –4.2 $\times$ ) in the affected knees compared to ACP dogs beginning 1 week after treatment and at each assessment time point throughout the 6-month post-treatment study period (Fig. 2B). There were no statistically significant



**Figure 5.** Representative arthroscopic images obtained one week after partial ACL transection and medial meniscal release (immediately prior to treatment) showing synovitis (A), retraction and remodeling at the ACL transection site (B), and complete subluxation of the medial meniscus (C) in the operated joint of a dog in this study.



( $p > 0.08$ ) differences in degree of effusion in the affected knees at any assessment time point throughout the 6-month post-treatment study period (Fig. 2C).

#### Lameness, Function, and Kinetics

Dogs in the Saline group had significantly ( $p < 0.05$ ) more severe lameness in the affected hindlimbs compared to ACP dogs at 5, 12, and 18 weeks after treatment (Fig. 3A). Dogs in the ACP group had significantly ( $p < 0.05$ ) higher function (10 cm VAS scale<sup>40,41</sup>) in the affected hindlimbs compared to Saline dogs at 5, 12, and 18 weeks after treatment (Fig. 3B). Dogs in the ACP group had significantly ( $p < 0.05$ ) higher %TPI in the affected hindlimbs compared to Saline dogs at 5, 12, and 18 weeks after treatment (Fig. 3C). No other statistically significant differences were noted throughout the study period.

#### Radiographic Scoring

Radiographic pathology was noted in all dogs prior to treatment in the form of moderate to severe effusion. Severity of radiographic OA increased significantly ( $p < 0.01$ ) over time within each group, however, no statistically significant ( $p > 0.2$ ) differences were noted between groups at any time point (Fig. 4).

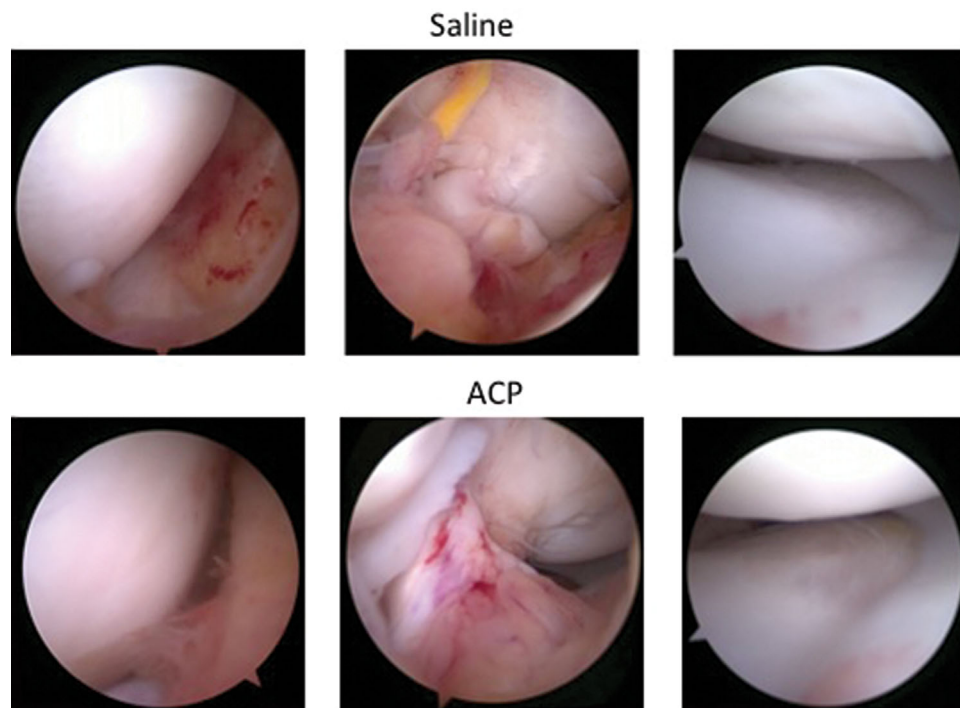
#### Arthroscopic Assessments

One week after partial ACL transection and medial meniscal release, and prior to treatment, the operated

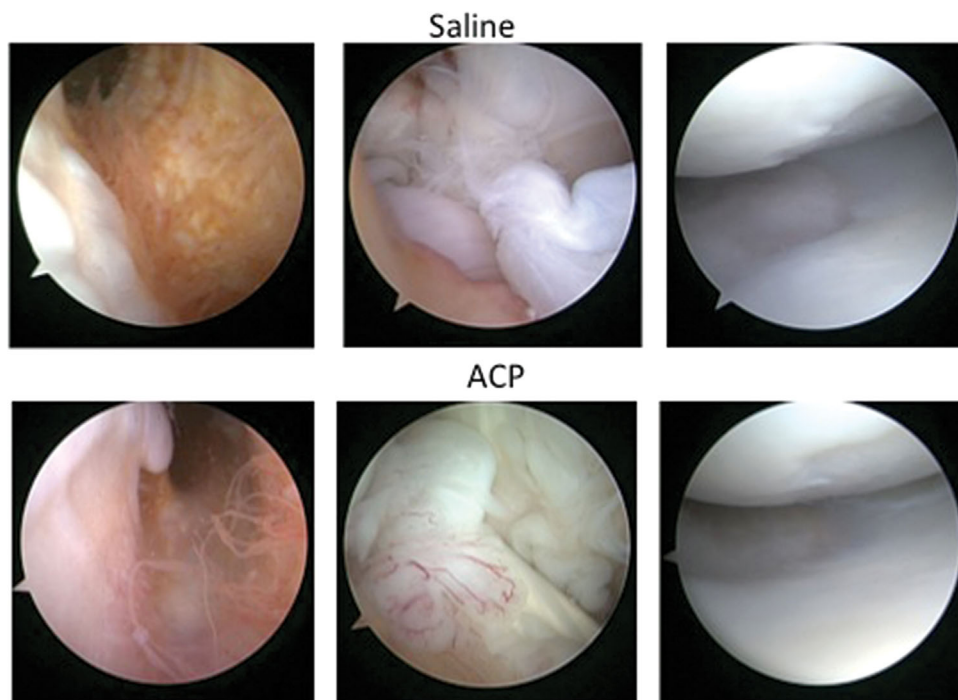
joints of all dogs showed very consistent pathologic findings of synovitis, retraction, and remodeling at the ACL transection site, and complete subluxation of the medial meniscus (Fig. 5).

Twelve weeks after treatment, knees treated with saline injections all showed moderate to severe synovitis, disruption of the anteromedial band of the ACL with associated vascular and synovial proliferation, and medial compartment cartilage loss (grade 2–3, primarily tibial). Knees treated with ACP injections also showed medial compartment cartilage loss (grade 2–3, primarily tibial), but the synovitis was less severe (mild to moderate) and five of six knees showed evidence of repair tissue at the site of ACL transection (Fig. 6).

Six months after treatment, knees treated with saline injections all showed moderate to severe chronic synovitis, further disruption of the anteromedial band of the ACL and three with partial disruption of the posterolateral band of the ACL, and medial compartment cartilage loss (grade 2–4 tibial and femoral). Knees treated with ACP injections also showed medial compartment cartilage loss (grade 2–4 tibial and femoral) with less severe chronic synovitis (mild to moderate) and five of six knees showed evidence of repair and remodeling at the site of ACL transection with one showing disruption of the anteromedial band of the ACL with associated vascular and synovial proliferation (Fig. 7).



**Figure 6.** Representative arthroscopic images obtained 12 weeks after treatment. Knees treated with saline injections (top row) all showed moderate to severe synovitis (left), disruption of the anteromedial band of the ACL with associated vascular and synovial proliferation (middle), and medial compartment cartilage loss (right). Knees treated with ACP injections (bottom row) showed less severe synovitis (left), evidence of repair tissue at the site of ACL transection in five of six knees (middle), and medial compartment cartilage loss (right).



**Figure 7.** Representative arthroscopic images obtained 6 months after treatment. Knees treated with saline injections (top row) all showed moderate to severe chronic synovitis (left), further disruption of the anteromedial band of the ACL and three with partial disruption of the posterolateral band of the ACL (middle), and medial compartment cartilage loss (right). Knees treated with ACP injections (bottom row) showed less severe chronic synovitis (left), evidence of repair, and remodeling at the site of ACL transection in five of six knees (middle), and medial compartment cartilage loss (right).

**Biomechanical Testing**

Although, ACL strength (force-to-displacement in anterior drawer) and stiffness in ACP-treated knees were numerically higher and closer to controls (normal ACLs) than in Saline-treated knees, none of the differences in material properties were statistically significant ( $p > 0.08$ ) (Fig. 8).

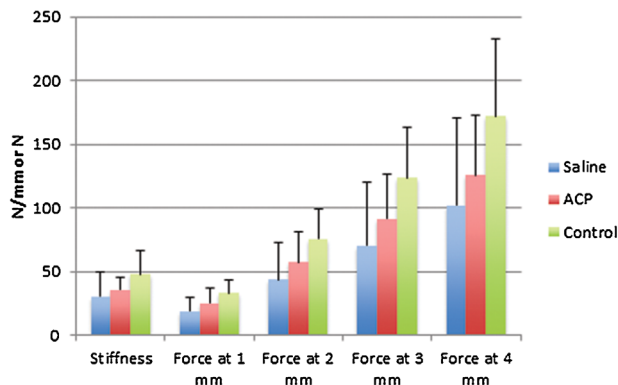
**Histology**

Based on whole-joint histologic assessments, synovial pathology was more severe in the Saline group, however, the difference was not statistically significant ( $p = 0.1$ ). ACL pathology was significantly ( $p < 0.05$ ) less severe in

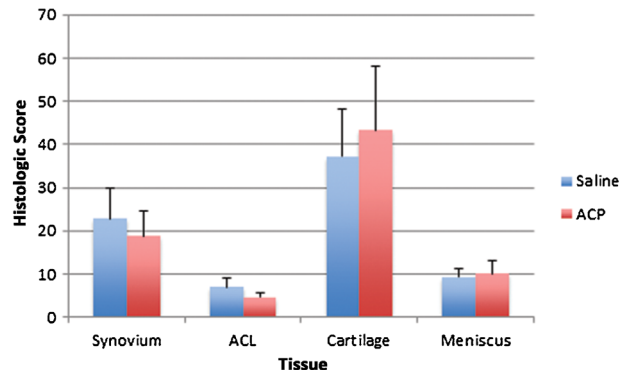
ACP-treated knees compared to Saline-treated knees. Severities of cartilage and meniscal pathology were not significantly ( $p > 0.5$ ) different between treatment groups (Fig. 9).

**DISCUSSION**

The results of this study allow us to accept the hypothesis that multiple intra-articular injections of a leukoreduced PRP would significantly reduce pain, improve functional limb use, and promote ACL repair, however, we must reject the hypothesis that these injections would promote meniscal healing and amelio-



**Figure 8.** Mean  $\pm$  SD values for ACL strength (force-to-displacement in anterior drawer) and stiffness in Saline-treated knees, ACP-treated knees, and Control knees. None of the differences in material properties were statistically significantly different among groups.



**Figure 9.** Mean  $\pm$  SD values for whole-joint histologic assessments performed in this study. ACL pathology was significantly ( $p < 0.05$ ) less severe in ACP-treated knees compared to Saline-treated knees. Severities of synovial, cartilage, and meniscal pathology were not significantly different between treatment group. (\*) indicates significant differences between groups.

rate progression of OA compared to saline injections. Partial ACL transection and medial meniscal release were effective in creating critical ACL and meniscal defects, medial compartment cartilage loss, synovitis, and whole-joint OA with associated radiographic changes, pain, and dysfunction, which were progressive over the 6-month study period. The results suggest that multiple injections of leukoreduced PRP had beneficial effects for ACL repair based on arthroscopic and histologic assessments. Multiple injections of leukoreduced PRP improved range of motion, decreased pain, and improved function for up to 6 months in dogs with knee OA. However, multiple injections of leukoreduced PRP did not beneficially affect meniscal healing in this model nor did they ameliorate the development or progression of OA compared to Saline controls based on radiographic, arthroscopic, and histologic assessments. Interestingly, the beneficial effects of PRP on knee range of motion and pain were noted 1 week after initiation of treatment and maintained throughout the 6-month study period. In contrast, the beneficial effects of PRP on lameness, function, and kinetics were not realized until 5 weeks after initiation of treatment (after 3 of 5 injections) and were no longer significantly different at the end of the 6-month study period. In conjunction with the radiographic, arthroscopic, and histologic findings with respect to development and progression of OA, these data suggest that mechanisms associated with the beneficial effects of PRP seen in this study are primarily related to its anti-inflammatory, analgesic, and viscoelastic effects rather than any direct effects on tissue anabolism or catabolism.<sup>1-9,34-39</sup>

A large body of current evidence regarding clinical use of PRP is focused on intra-articular injections of PRP alone in the management of OA. The preponderance of the evidence supports the use of leukoreduced PRP for intra-articular injections, and suggests that leukoreduced PRP is a safe and effective option for palliation in OA with consistent benefits over saline and hyaluronic acid controls and cohorts.<sup>1-9,34-39</sup> While animal model studies have suggested that PRP plus scaffold can be effective in enhancing ACL repairs and reconstructions,<sup>10,12,15-21</sup> the present study is the first to show efficacy of intra-articular PRP alone in promoting improved arthroscopic and histologic characteristics of repair and benefits to function and kinetics for dogs with partial ACL tears.

Injections of PRP alone were not effective in promoting meniscal healing in this model. This is likely due to difficulty in promoting meniscal healing in general, the lack of a scaffold for the PRP, and the severity of model. The meniscal release models the most biomechanically severe meniscal tear in that it is a complete radial transection with elimination of all hoop-stress capabilities of the remaining tissue.<sup>41</sup> This model was chosen for the present study in order to induce OA rather than to provide a model for investigating PRP-related meniscal repair and/or tissue pres-

ervation. Based on this objective, the model was effective. Different models for meniscal pathology need to be investigated to appropriately determine the direct effects of multiple injection of PRP on meniscal healing.

The limitations of the present study include the use of an animal model in which the pathologic conditions were surgically induced, and the number and timing of intra-articular injections included in the study design. While the canine model used does not exactly mimic clinical ACL and meniscal tears, which would typically not be left untreated, partial ACL transection, and medial meniscal release did result in critical ACL, and meniscal defects, whole-joint osteoarthritis and associated symptoms, which were progressive over the 6-month study period. Based on these findings and the use of normal contralateral knee and placebo (saline injection) controls, the results of the study are valid with respect to the relative effects of PRP for both safety and efficacy. The use of five intra-articular injections over the first 8 weeks following insult to the joint may pose challenges to clinical application with respect to patient acceptance, logistics and costs. Ongoing studies in our laboratory are aimed at determining the minimal effective dosing strategy in order to realize the benefits of intra-articular PRP injections noted in this study in the most clinically applicable way.

## CONCLUSIONS

The results of the present study suggest that five intra-articular injections of leukoreduced PRP over the first 8 weeks following partial ACL transection and meniscal release had beneficial effects for ACL repair, improved range of motion in the knee, decreased pain, and improved limb function for up to 6 months in a pre-clinical canine model. Based on these findings, we concluded that leukoreduced PRP has potential benefits in promoting ACL healing and treating symptoms associated with knee OA. We are now working to optimize a clinically applicable strategy for use of PRP in treating patients with ACL injuries.

## AUTHORS' CONTRIBUTIONS

All authors have read and approved the final submitted article. The following in the author contribution: JLC, PAS, CCB, KK, CRC, AMS, FMP: substantial contributions to research design, acquisition, analysis of interpretation of data; JLC, PAS, CCB, KK, CRC, drafting the paper and revising it critically; JLC, PAS, CCB, KK, CRC, AMS, FMP: approval of the submitted and final versions.

## ACKNOWLEDGMENTS

Arthrex Inc. provided research support for this project. JL Cook, PA Smith, and CR Cook have received support from Arthrex Inc. as either paid consultants, for speakers bureau/paid presentations, or for project research support. JL Cook receives patent royalties from Arthrex for unrelated products.

## REFERENCES

1. Stannard JP, Cook JL, Fortier LA. 2015. *Biologics in orthopaedic surgery*. New York: Thieme Medical Publishers, Inc. 2015 ISBN: 978162623
2. Hsu WK, Mishra A, Rodeo SR, et al. 2013. Platelet-rich plasma in orthopaedic applications: evidence-based recommendations for treatment. *J Am Acad Orthop Surg* 21:739–748.
3. Riboh JC, Satlzman BM, Yanke AB, et al. 2015. Effect of leukocyte concentration on the efficacy of platelet-rich plasma in the treatment of knee osteoarthritis. *Am J Sports Med* [Epub ahead of print] pii: 0363546515580787.
4. Lai LP, Stitik TP, Foye PM, et al. 2015. Use of platelet-rich plasma in intra-articular knee injections for osteoarthritis: a systematic review. *PMR* 7:637–648.
5. Campbell KA, Satlzman BM, Mascarenhas R, et al. 2015. Does intra-articular platelet-rich plasma injection provide clinically superior outcomes compared with other therapies in the treatment of knee osteoarthritis? A systematic review of overlapping meta-analyses. *Arthroscopy* [Epub ahead of print] pii: S0749-8063(15)00353-9. doi: 10.1016/j.arthro. 2015.03.041
6. Bashir J, Panero AJ, Sherman AL, et al. 2015. The emerging use of platelet-rich plasma in musculoskeletal medicine. *J Am Osteopath Assoc* 115:24–31.
7. Beitzel K, Allen D, Apostolakis J, et al. 2015. US definitions, current use, and FDA stance on use of platelet-rich plasma in sports medicine. *J Knee Surg* 28:29–34.
8. Fiorentino S, Roffi A, Filardo G, et al. 2015. European definitions, current use, and EMA stance of platelet-rich plasma in sports medicine. *J Knee Surg* 28:51–54.
9. Mascarenhas R, Saltzman BM, Fortier LA, et al. 2015. Role of platelet-rich plasma in articular cartilage injury and disease. *J Knee Surg* 28:3–10.
10. Hutchinson ID, Rodeo SA, Perrone GS, et al. 2015. Can platelet-rich plasma enhance anterior cruciate ligament and meniscal repair? *J Knee Surg* 28:19–28.
11. Andia I, Maffulli N. 2015. Use of platelet-rich plasma for patellar tendon and medial collateral ligament injuries: best current clinical practice. *J Knee Surg* 28:11–18.
12. Murray MM, Palmer M, Abreu E, et al. 2009. Platelet-rich plasma alone is not sufficient to enhance suture repair of the ACL in skeletally immature animals: an in vivo study. *J Orthop Res* 27:639–645.
13. Murray MM, Fleming BC. 2013. Use of a bioactive scaffold to stimulate anterior cruciate ligament healing also minimizes posttraumatic osteoarthritis after surgery. *Am J Sports Med* 41:1762–1770.
14. Steiner ME, Murray MM, Rodeo SA. 2008. Strategies to improve anterior cruciate ligament healing and graft replacement. *Am J Sports Med* 36:176–189.
15. Vavken P, Fleming BC, Mastrangelo AN, et al. 2012. Biomechanical outcomes after bioenhanced anterior cruciate ligament repair and anterior cruciate ligament reconstruction are equal in a porcine model. *Arthroscopy* 28:672–680.
16. Murray MM, Magarian E, Zurakowski D, et al. 2010. Bone-to-bone fixation enhances functional healing of the porcine anterior cruciate ligament using a collagen-platelet composite. *Arthroscopy* 26:S49–S57.
17. Murray MM, Spindler KP, Ballard P, et al. 2007. Enhanced histologic repair in a central wound in the anterior cruciate ligament with a collagen-platelet-rich plasma scaffold. *J Orthop Res* 25:1007–1017.
18. Murray MM, Spindler KP, Abreu E, et al. 2007. Collagen-platelet-rich plasma hydrogel enhances primary repair of the porcine anterior cruciate ligament. *J Orthop Res* 25:81–91.
19. Joshi SM, Mastrangelo AN, Magarian EM, et al. 2009. Collagen-platelet composite enhances biomechanical and histologic healing of the porcine anterior cruciate ligament. *Am J Sports Med* 37:2401–2410.
20. Spindler KP, Murray MM, Carey JL, et al. 2009. The use of platelets to affect functional healing of an anterior cruciate ligament (ACL) autograft in a caprine ACL reconstruction model. *J Orthop Res* 27:631–638.
21. Fleming BC, Spindler KP, Palmer MP, et al. 2009. Collagen-platelet composites improve the biomechanical properties of healing anterior cruciate ligament grafts in a porcine model. *Am J Sports Med* 37:1554–1563.
22. Fleming BC, Proffen BL, Vavken P, et al. 2015. Increased platelet concentration does not improve functional graft healing in a bio-enhanced ACL reconstruction. *Knee Surg Sports Traumatol Arthrosc* 23:1161–1170.
23. Vavken P, Sadoghi P, Murray MM. 2011. The effect of platelet concentrates on graft maturation and graft-bone interface healing in anterior cruciate ligament reconstruction in human patients: a systematic review of controlled trials. *Arthroscopy* 27:1573–1583.
24. Orrego M, Larrain C, Rosales J, et al. 2008. Effects of platelet concentrate and a bone plug on the healing of hamstring tendons in a bone tunnel. *Arthroscopy* 24:1373–1380.
25. Sánchez M, Anitua E, Azofra J, et al. 2010. Ligamentization of tendon grafts treated with an endogenous preparation rich in growth factors: gross morphology and histology. *Arthroscopy* 26:470–480.
26. Radice F, Yáñez R, Gutiérrez V, et al. 2010. Comparison of magnetic resonance imaging findings in anterior cruciate ligament grafts with and without autologous platelet-derived growth factors. *Arthroscopy* 26:50–57.
27. Ventura A, Terzaghi C, Borgo E, et al. 2005. Use of growth factors in ACL surgery: preliminary study. *J Orthopaed Traumatol* 6:76–79.
28. Vogrin M, Ruprecht M, Dinevski D, et al. 2010. Use of a platelet gel on early graft revascularization after anterior cruciate ligament reconstruction: a prospective, randomized, double-blind clinical trial. *Eur Surg Res* 45:77–85.
29. Figueroa D, Melean P, Calvo R, et al. 2010. Magnetic resonance imaging evaluation of the integration and maturation of semitendinosus-gracilis graft in anterior cruciate ligament reconstruction using autologous platelet concentrate. *Arthroscopy* 26:1318–1325.
30. Nin JR, Gasque GM, Azcárate AV, et al. 2009. Has platelet-rich plasma any role in anterior cruciate ligament allograft healing? *Arthroscopy* 25:1206–1213.
31. Silva A, Sampaio R. 2009. Anatomic ACL reconstruction: does the platelet-rich plasma accelerate tendon healing? *Knee Surg Sports Traumatol Arthrosc* 17:676–682.
32. Boswell SG, Cole BJ, Sundman EA, et al. 2012. Platelet-rich plasma: a milieu of bioactive factors. *Arthroscopy* 28:429–439.
33. Ishida K, Kuroda R, Miwa M, et al. 2007. The regenerative effects of platelet-rich plasma on meniscal cells in vitro and its in vivo application with biodegradable gelatin hydrogel. *Tiss Eng* 13:1103–1112.
34. Filardo G, Kon E, Roffi A, et al. 2015. Platelet-rich plasma: why intra-articular? A systematic review of the preclinical studies and clinical evidence on PRP for joint degeneration. *Knee Surg Sports Traumatol Arthrosc* 23:2459–2474.
35. Filardo G, Kon E, Buda R, et al. 2011. Platelet-rich plasma intra-articular knee injections for the treatment of degenerative cartilage lesions and osteoarthritis. *Knee Surg Sports Traumatol Arthrosc* 19:528–535.
36. Patel S, Dhillon MS, Aggarwal S, et al. 2013. Treatment with platelet-rich plasma is more effective than placebo for



- knee osteoarthritis: a prospective, double-blind, randomized trial. *Am J Sports Med* 41:356–364.
37. Andia I, Maffulli N. 2013. Platelet-rich plasma for managing pain and inflammation in osteoarthritis. *Nat Rev Rheumatol* 9:721–730.
  38. Sundman EA, Cole BJ, Karas V, et al. 2014. The anti-inflammatory and matrix restorative mechanisms of platelet-rich plasma in osteoarthritis. *Am J Sports Med* 42:35–41.
  39. Sakata R, McNary SM, Miyatake K, et al. 2015. Stimulation of the superficial zone protein and lubrication in the articular cartilage by human platelet-rich plasma. *Am J Sports Med* 43:1467–1473.
  40. Hudson JT, Slater MR, Taylor L, et al. 2004. Assessing repeatability and validity of a visual analogue scale questionnaire for use in assessing pain and lameness in dogs. *Am J Vet Res* 65:1634–1643.
  41. Luther JK, Cook CR, Cook JL. 2009. Meniscal release in cruciate ligament intact stifles causes lameness and medial compartment cartilage pathology in dogs 12 weeks post operatively. *Vet Surg* 38:520–529.
  42. Mainil-Varlet P, Aigner T, Brittberg M, et al. 2003. Histological assessment of cartilage repair: a report by the histology endpoint committee of the international cartilage repair society (ICRS). *J Bone Joint Surg Am* 85-A:45–57.
  43. Cook JL, Kuroki K, Visco D, et al. 2010. The OARSI histopathology initiative- recommendations for histological assessments of osteoarthritis in the dog. *Osteoarthritis Cartilage* 18:S66–S79.
  44. Choate CJ, Lewis DD, Conrad BP, et al. 2013. Assessment of the craniocaudal stability of four extracapsular stabilization techniques during two cyclic loading protocols: a cadaver study. *Vet Surg* 42:853–859.
  45. Cook JL, Luther JK, Beetem J, et al. 2010. Clinical comparison of a novel extracapsular stabilization procedure and tibial plateau leveling osteotomy for treatment of cranial cruciate ligament deficiency in dogs. *Vet Surg* 39:315–323.
  46. Lopez MJ, Markel MD. 2003. Anterior cruciate ligament rupture after thermal treatment in a canine model. *Am J Sports Med* 31:164–167.
  47. Mullaji AB, Marawar SV, Simha M, et al. 2008. Cruciate ligaments in arthritic knees: a histologic study with radiologic correlation. *J Arthroplasty* 23:567–572.